UDC 617.55.-089.844

RESULTS OF THE EXPERIMENTAL SUBSTANTI ATION OF AN IMPROVED METHOD FOR THE TREATMENT OF VENTRAL HERNIAS

Norov F.X
Bukhara State Medical Institute, Uzbekistan

Abstract:*To date, despite the achievement of certain successes in the treatment of hernias, many issues of herniology remain unresolved and controversial. Therefore, the development and introduction into surgical practice of more effective methods of hernia treatment aimed at determining the gradations of histocompatibility of the tissues of the anterior abdominal wall with various synthetic materials, as well as a differentiated approach to the choice of allomaterial, determine the relevance of this problem and its important social significance. The purpose of the study was to evaluate the results of histocompatibility of alloprostheses using several types of prosthetic materials on an experimental model of external abdominal hernias. Experimental studies were carried out in the TMA vivarium on New Zealand White rabbits with an average weight of 5 kg (4600-5400 grams) in strict compliance with the requirements of the European Convention for the Protection of Vertebrate Animals used for experimental and other scientific purposes. Experimental animals were made 4 transverse sections 3 cm long on both sides of the midline. After preparing the site for alloplasty, each experimental animal was implanted with various alloplasties (thin porous polypropylene, large porous polypropylene, ultrapro, acrylic) with dimensions of 3.0x1.0 cm. On the 10th and 45th days, the material was taken and morphological studies were performed to assess the degree implant adhesion. Thus, we improved the experimental model of external abdominal hernias, which consisted in the fact that several types of allomaterials were implanted on one experimental animal in equivalent areas of the anterior abdominal wall, which made it possible to achieve identical conditions for the healing of various allomaterials. Taking into account the different physicochemical properties of the meshes, we conducted experimental studies on the healing of various allografts.*

Key words: *ventral hernia, alloprosthetics, hernia orifice plasty, experimental model*

РЕЗУЛЬТАТЫ ЭКСПЕРИМЕНТАЛЬНОЙ ОБОСНОВАНИЕ УСОВЕРШЕНСТВОВАННОГО МЕТОДА ЛЕЧЕНИЯ ВЕНТРАЛЬНЫХ ГРЫЖ

Норов Ф.Х.
Бухарский государственный медицинский институт, Узбекистан

Резюме: *На сегодняшний день несмотря на достижения определенных успехов в лечении грыж, многие вопросы герниологии остаются нерешёнными и спорными.*

Следовательно, разработка и внедрение в хирургическую практику более эффективных методов лечения грыж, направленных на определение градаций гистосовместимости тканей передней брюшной стенки с различными синтетическими материалами, а также дифференцированный подход к выбору алломатериала, определяют актуальность данной проблемы и ее важное социальное значение. Цель исследования оценить результатов гистосовместимости аллопротезов при использовании нескольких видов протезирующих материалов на экспериментальная модель наружных грыж живота. Экспериментальные исследования были проведены в виварии ТМА на кроликах породы новозеландская белая со средней массой 5 кг (4600-5400 грамм) с строгим соблюдением требований Европейской конвенции по защите позвоночных животных, используемых для экспериментальных и других научных целей. У экспериментальных животных были сделаны 4 поперечных среза длиной 3 см по обе стороны от средней линии. После подготовки площадки для аллопластики каждому подопытному животному имплантировали различные аллопластики (тонкий пористый полипропилен, крупнопористый полипропилен, ультрапро, акрил) размерами 3, 0х1, 0 см. На 10-й и 45-й день был взят материал и проведены морфологические исследования для оценки степени адгезии имплантата. Таким образом, нами была усовершенствована экспериментальная модель наружных грыж живота, которая заключалась в том, что на одном экспериментальном животном имплантировали несколько разновидностей алломатериалов на равнозначных участках передней брюшной стенки, что позволяло достичь идентичности условий для заживления различных алломатериалов. Учитывая различные физико-химические свойства сеток, нами проведены экспериментальные исследования по изучению заживления различных аллотрансплантатов.

Ключевые слова*: вентральная грыжа, аллопротезирование, пластики грыжевых ворот, экспериментальная модель*

ВЕНТРАЛ ЧУРРАЛАРНИ ТАКОМИЛЛАШТИРИЛГАН ДАВОЛАШ УСУЛИНИ ЭКСПЕРИМЕНТАЛ АСОСЛАШ НАТИЖАЛАРИ

Норов Ф.Х
Бухоро давлат тиббиёт институти, Ўзбекистон

Резюме: *Бугунги кунда чурраларни даволашда маълум ютуқларга эришилганига қарамай, герниологиянинг кўплаб масалалари ҳал этилмаган ва мунозарали бўлиб қолмоқда. Шу сабабли, қорин олд девори тўқималарининг турли хил синтетик материаллар билан гистологик мувофиқлиги градацияларини аниқлашга қаратилган чуррани даволашнинг янада самарали усулларини ишлаб*

чиқиш ва жарроҳлик амалиётига жорий этиш, шунингдек, алломатериални танлашда табақалаштирилган ёндашув, ушбу муаммонинг долзарблиги ва унинг муҳим ижтимоий аҳамиятини белгилайди. Тадқиқотнинг мақсади ташқи қорин чурраларининг экспериментал модели бўйича бир неча турдаги протез материалларидан фойдаланган ҳолда аллопротезларнинг гисто-мувофиқлиги натижаларини баҳолашдан иборат. Экспериментал тадқиқотлар ТТА вивариясида ўртача оғирлиги 5 кг (4600-5400 грамм) бўлган Янги Зеландия оқ қуёнларида экспериментал ва бошқа илмий мақсадларда фойдаланиладиган умуртқали ҳайвонларни ҳимоя қилиш бўйича Европа конвенцияси талабларига қатъий риоя қилган ҳолда (Страсбург, 1986) ўтказилган. Тажриба ҳайвонларида ўрта чизиқнинг икки томонида узунлиги 3 см гача бўлган 4 та кесма амалга оширилган. Аллопластика учун майдонча тайёрлангач ҳар бир тажриба ҳайвонига ўлчамлари 3,0х1,0 см бўлган турли хил аллопротезлар (нозик ғовакли полипропилен, катта ғовакли полипропилен, ультрапро, акрил) имплантация қилинган. 10 ва 45-кунларда имплантатнинг битиш даражасини баҳолаш учун материал олинган ва морфологик тадқиқотлар ўтказилган. Шу мақсадда белгиланган муддатда тажрибадан биттадан қуён олинган ва тадқиқот учун алломатериал имплантация зонасидан тўқималар олинган. Хулоса қилиб айганда, қорин ташқи чурраларининг экспериментал моделини такомиллаштириш бир нечта турдаги алломатериаллар битта экспериментал ҳайвон қорин олд деворининг ўхшаш жойларига имплантация қилинганидан иборат бўлиб, бу турли хил алломатериалларни битказиш учун бир хил шароитларга эришишга имкон берди. Тўрларнинг турли хил физик-кимёвий хусусиятларини ҳисобга олган ҳолда, турли хил аллотрансплантатларнинг битишини ўрганиш бўйича экспериментал тадқиқотлар ўтказилди.

Калит сўзлар*: вентрал чурра, аллопротезлаш, чурра дарвозасини протезалш, экспериментал модель*

In the world, one of the most common surgical pathologies is external abdominal hernia. The proportion of “...postoperative ventral hernias account for up to 15-18% of the total number of patients with abdominal hernias. More than 1.5 million surgical interventions for ventral hernias are performed annually in the world, in the CIS countries this figure exceeds 200,000 operations…” [1, 2]. Moreover, the incidence of Postoperative ventral hernia (POVH) is directly proportional to the number of performed laparotomies. POVH develops in 5-30% of patients after median laparotomy. It should be noted that "... a hernia recurrence after surgery occurs in 29% of patients, after elimination of the first recurrence 35%, the second 39%..." [4, 6].

All over the world there are many methods of hernia repair in postoperative ventral hernias. The most common method was plastic surgery using local fabrics, the frequency of which decreases from year to year. At the same time, hernia recurrence in patients

was up to 20%, and in complicated forms it exceeded 40%. The solution to the problems of treating patients with abdominal hernias was found in the widespread use of allomaterials. “... when strengthening the abdominal wall with mesh endoprostheses, the recurrence rate decreased to 2-3%, but the risk of developing complications from the postoperative wound in the early and late postoperative periods increased ...” [8, 9]. One of the main reasons for the increase in the frequency of postoperative complications was the presence of an alloprosthesis as a "foreign body" in the tissues of the anterior abdominal wall. “…this contributed to the development of various wound complications in the form of seroma, suppuration of postoperative wounds, which often led to rejection of the allograft…” [7, 10, 12].

Large-scale work is being carried out in our country to socially protect the population and improve the healthcare system. In this direction, in particular, in improving the surgical treatment of patients with postoperative ventral hernias, positive changes have been achieved. At the same time, to improve the care provided to patients, evidence-based results are required to evaluate the effectiveness of surgical intervention, taking into account the prevention of intraoperative and postoperative complications. The most common cause of postoperative complications is that the biosynthetic materials used during plasty, despite their diversity, do not always meet the requirements, causing a local reaction, and can lead to the development of suppurative complications, which may be the causes of further recurrence of POVH and the development of more severe complications. as an allograft rejection [3, 5, 11].

Despite the achievement of certain successes in the treatment of hernias, many issues of herniology remain unresolved and controversial. Therefore, the development and introduction into surgical practice of more effective methods of hernia treatment aimed at determining the gradations of histocompatibility of the tissues of the anterior abdominal wall with various synthetic materials, as well as a differentiated approach to the choice of allomaterial, determine the relevance of this problem and its important social significance.

Purpose of the study: to evaluate the results of histocompatibility of alloprostheses using several types of prosthetic materials on an experimental model of external abdominal hernias.

Material and methods. Experimental studies were carried out in the TMA vivarium on New Zealand White rabbits with an average weight of 5 kg (4600-5400 grams) in strict compliance with the requirements of the European Convention for the Protection of Vertebrate Animals used for experimental and other scientific purposes (Strasburg, 1986). The studies were carried out under general anesthesia, which was carried out by intravenous administration of sodium thiopental (5% rasters at the rate of 0.5 ml per 1 kg.) into the marginal ear vein. 10-15 ml of 0.5% novocaine solution was additionally injected into the incision area.

Experimental animals were made 4 transverse sections 3 cm long on both sides of the midline. After preparing the site for alloplasty, each experimental animal was implanted with various alloplasties (thin porous polypropylene, large porous polypropylene, ultrapro, acrylic) with dimensions of 3.0x1.0 cm. On the 10th and 45th days, the material was taken and morphological studies were performed to assess the degree implant adhesion. For this purpose, one rabbit was withdrawn from the experiment during the specified period of time, and tissue from the allomaterial implantation zone was taken for research.

After conducting experimental studies and sampling material, morphological studies were carried out in the pathomorphological laboratory "Ipsum Pathology". The material was stored in 10% formalin solution. After dehydration of the material, paraffinization was carried out and preparations were prepared by staining with hematoxylin and eosin. The study of the morphological picture was carried out under a light microscope. Morphological studies were performed for all experimental animals. When collecting clinical material, morphological studies were performed in all patients. We studied the state of the hernial sac, the removed skin-fat flap, as well as the state of the removed organs and tissues (when performing such operations).

Statistical processing of the material was carried out on a Core I7 11400H personal computer in the Windows NT 11 operating system using the Microsoft Excel 2016 software package using the built-in statistical processing functions. To achieve the set goal and carry out the necessary statistical processing, the mean value (M) and the mean deviation (m) were calculated. Significance of differences between the studied criteria of clinical groups was carried out using the Student's coefficient. Differences were considered significant at t-Student equal to or greater than 2.0 or the probability of coincidence was less than 5%.

Research results: The analysis of existing models of external abdominal hernias made it possible to determine their main shortcomings, which, from our point of view, require a certain correction:

- The impossibility of obtaining a "standardized" hernia with given physiological parameters in all experimental animals;
- It is not excluded the possibility of changing the microbial landscape of the wound during the experiment;
- The impossibility of selecting absolutely identical experimental animals according to the initial state and the same reaction to the implanted allomaterial;
- Lack of identity of the course of the wound process and healing processes in various experimental animals.

Due to the maximum efficiency of existing models of external abdominal hernia and the possibility of technical reproduction of a new method of hernia treatment, not all of them are able to create absolutely identical conditions for assessing the occurrence of allomaterials that differ in structure, physical state and chemical composition.

To level the fact of the influence of various factors on the healing processes of meshes in various experimental animals, we have developed an experimental model for

assessing the histocompatibility of alloprostheses using several types of prosthetic materials.

For this, 4 separate incisions up to 3.0 cm long were made on the experimental animal (rabbit) parallel to the midline of the abdomen. After preparing the site for alloplasty, various alloprostheses were implanted (Fig. 1.).

Figure 1. Improved experimental hernia model.

It should be noted that this principle of creating an experimental model is quite applicable in the development of experimental models of a local nature (postoperative wounds, purulent wounds, volumetric formations of soft tissues, etc.), however, they cannot be used when reproducing diseases of a general nature and prevalence. .

When classifying materials for hernioplasty in the experiment of N. M. Classification outlined in the work of Urmanova (2022)

For experimental studies, 4 groups of allomaterials according to the above classification were used. Experimental studies were carried out in the operating room of the TMA vivarium, where all aseptic and antiseptic measures were observed. Under general thiopental anesthesia with additional local anesthesia, 4 incisions up to 3 cm long were made in four experimental animals on both sides of the midline. The mesh was sutured to the aponeurosis using synthetic non-absorbable monofilament sutures of the prolene type with continuous sutures. Hemostasis control. The wound was sutured in layers, tightly. An aseptic bandage was applied. On the 10th and 45th days, material was taken and morphological studies were performed to assess the degree of implant healing. For this purpose, one rabbit was taken out of the experiment at the specified time, and tissues were taken from the area of allomaterial implantation for research (Fig. 2).

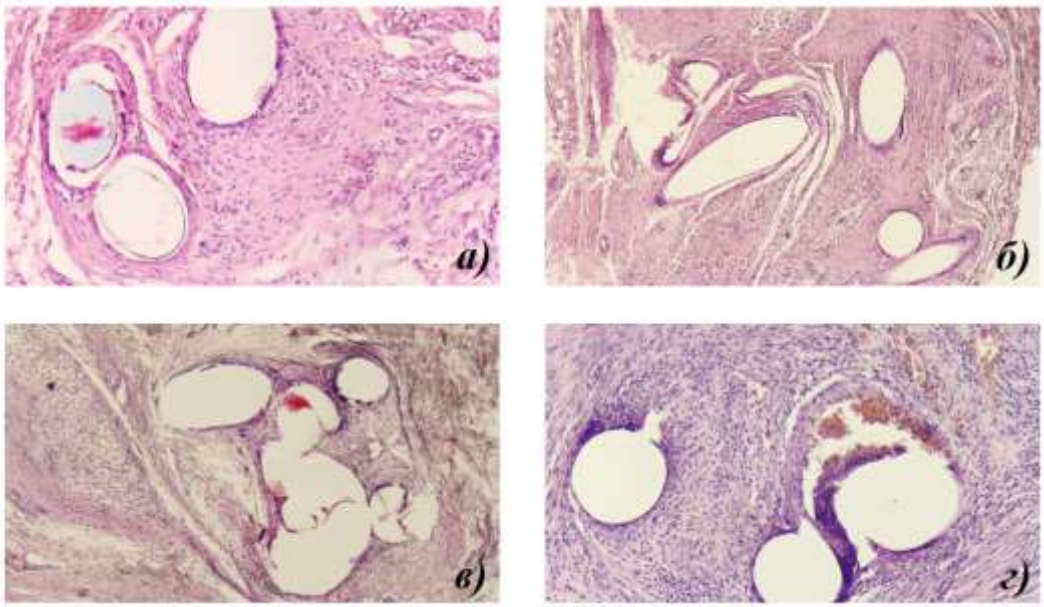

Figure 2. Microscopic image of tissues after application of 4 types of allomaterials Day 45 (approx. 10. et al. 20.): a) Ultrapro. mesh fibers. Hematok. old eosin. color; b) Acrylic. Swelling and homogenization of mesh fibers. Hematok. and eosin; c) large-pore polypropylene. Vascular reaction, thickening of interstitial collagen. Hematok. old eosin. color; d) finely porous polypropylene. Increased lymphoid infiltration. Hematok. eosin. color.

The conducted morphological studies showed that in acrylic, ultraporous, large-porous polypropylene types, regenerative processes proceeded relatively evenly, in combination with free penetration of fibroblasts and subsequent growth of collagen fibers both around nodal joints and around single-layer implants, with less cicatricial changes close to physiological . When using a large pore mesh, large pores caused more natural fibroblastic infiltration. Acrylic and ultrapro have the best repair rates, since some fibers are hydrolyzed, making room for the connective tissue growing in them, while the percentage of a foreign body remaining in the body and the reaction to it are also minimized.

When using especially finely porous polypropylene, a more pronounced inflammatory and fibroblast reaction was observed with the formation of dense, hypertrophied connective fibers. This is due to an excess of insoluble synthetic material that stimulates the proliferation of fibroblasts, a disproportionate growth of regenerating tissues for the species, a more pronounced inflammatory reaction that activates collagenization.

Conclusion: Thus, we improved the experimental model of external abdominal hernias, which consisted in the fact that several types of allomaterials were implanted on one experimental animal in equivalent areas of the anterior abdominal wall, which made it possible to achieve identical conditions for the healing of various allomaterials. Considering the different physicochemical properties of the meshes, we carried out experimental studies on the healing of various allografts.

REFERENCES:

1. Гегия Б.Ш., Алаутдинов Р. Р. “Гибридная методика лечения послеоперационной вентральной грыжи” хирургия, 2018, Т4, с 24 – 30.
2. Давлатов С.С. Послеоперационные вентральные грыжи: современное состояние проблемы // Проблемы биологии и медицины. – 2019. – № 1. – С. 168-174.
3. Давлатов С.С. Качество жизни больных с послеоперационной вентральной грыжей в отдаленном периоде // Вестник врача. – 2019. – № 1. – С. 21–25.
4. Инютин А.С. Профилактика послеоперационных срединных вентральных грыж в ургентной абдоминальной хирургии: Дисс. на соис. уч. степ. док. мед. наук. – Рязань, 2021. – 292 с.
5. Кукош М.В., Власов А. В., Гомозов Г. И. Профилактика ранних послеоперационных осложнений при эндопротезировании вентральных грыж // Новости хирургии. – 2012. – Т. 20, № 5. – С. 32–37
6. Норов Ф. Х., Алекян Б. Г., Пурсанов М. Г. осложнения рентгеноэндоваскулярных лечебных вмешательств у пациентов старше одного года с врождёнными пороками сердца //Вестник Авиценны. – 2011. – №. 3. – С. 19-26.
7. Хикматов Жасур Сафарович. (2016). Хирургияда вентрал чурраларда ўтказиладиган протезли пластика амалиёти натижаларини яхшилаш йўллари (Магистрлик иши диссертацияси). Zenodo. https://doi.org/10.5281/zenodo.7117353.
8. Burner G., Montgomery A. Suture-Tool: A Mechanical Needle Driver for Standardized Wound Closure // World J Surg. – 2020. – Vol. 44, № 1. – P. 95-99.
9. Dindo D – Annals of surgery, 2004, vol.2, №240, p 205 – 213.
10. Garcia-Urena M.A. Preventing incisional ventral hernias: important for patients but ignored by surgical specialities? A critical review // Hernia. – 2021. – Jan 4. P. 121-125.
11. Hikmatov J.S. Influence of intestinal microflora on the development of gallstone disease (literature review) //Вопросы науки и образования. – 2021. – №. 18 (143). – С. 29-40.
12. Norov F.Kh., Muazzamov B.B. A new technology of treatment in patients with complex ventral hernias. International journal for innovative engineering and management research. 2021, P. 237-240