

MORFOLOGICAL FORMS OF RECURRENT PULMONARY ECHINOCOCCOSIS

Sharipov Umidjon Muzaffarovich

Islamov Shavkat Eryigitovich

Makhmatmuradova Nargiza Negmatullaevna

Samarkand State Medical University

Department of Pathological Anatomy

Department of Internal Medicine №4

Abstract: *The article is devoted to the morphological characteristics of recurrent pulmonary echinococcosis. The aim of the study was to establish the morphological forms of echinococcal cysts in patients with recurrent echinococcosis of the lungs. Immediate complications after surgery were observed in 6(11.3%) patients. An analysis of the morphological characteristics of echinococcal cysts of the lungs showed that recurrent echinococcosis was most often found in Echinococcus veterinorum (50.9%), Echinococcus hominis (37.7%), and in Echinococcus acephalocystis no relapses of the disease were observed, and if they did occur (6 – 11.3%), it was associated with the reinvasion of the parasite.*

Key words: *pulmonary echinococcosis, morphology, modifications.*

Аннотация: *Статья посвящена морфологической характеристике рецидивирующего эхинококкоза легких. Цель исследования - установление морфологических форм эхинококковых кист у больных с рецидивирующим эхинококкозом легких. Непосредственные осложнения после операции наблюдались у 6 (11,3%) пациентов. Анализ морфологических особенностей эхинококковых кист легких показал, что среди форм рецидивирующего эхинококкоза наиболее часто встречался Echinococcus veterinorum (50,9%), Echinococcus hominis (37,7%), а при Echinococcus acephalocystis рецидивов заболевания не наблюдалось, а если и встречались (6 – 11,3%), то было связано с реинвазией паразита.*

Ключевые слова: *эхинококкоз легких, морфология, модификации.*

Annotatsiya: *Maqola takroriy o'pka exinokokkozining morfologik xususiyatlariga bag'ishlangan. Tadqiqotning maqsadi takroriy o'pka exinokokkozli bemorlarda gidatid kistalarning morfologik shakllarini aniqlash edi. Operatsiyadan keyingi darhol asoratlar 6 (11,3%) bemorda kuzatildi. O'pkaning exinokokk kistalarining morfologik xususiyatlarini tahlil qilish shuni ko'rsatdiki, takroriy exinokokkoz shakllari orasida Echinococcus veterinorum (50,9%), Echinococcus hominis (37,7%) va Echinococcus asephalocystis kasalligining qaytalanishi kuzatilmagan. va agar ular ro'y bergan bo'lsa (6 - 11,3%), bu parazitning reinvaziyasi bilan bog'liq edi.*

Kalit so'zlar: *o'pka exinokokkozi, morfologiyasi, modifikatsiyalari.*

RELEVANCE

According to the latest data, human echinococcosis continues to be a severe parasitic disease. According to the WHO and a number of other sources, there is a widespread occurrence and a significant increase in the incidence among the population [3,7]. Along with the increase in the number of new cases of the disease, there is a large percentage of relapses of echinococcosis, the frequency of which, according to different authors, varies widely from 3.3 to 54%, which is due to the existing terminological confusion [1,4,5,6]. It is also necessary to note the increase in the number of errors made both in the diagnosis of this pathology and in the establishment of others [8,9,10].

The aim of the study was to establish the morphological forms of echinococcal cysts in patients with recurrent echinococcosis of the lungs.

Material and methods. In the surgical department of the 1st clinic of the Samarkand State Medical University, 53 patients with recurrent echinococcosis of the lungs were operated on. Among the instrumental methods of research, radiography, computed tomography and ultrasound were used according to indications. The analysis of morphological modifications of echinococcal lesions of the lungs was carried out.

Results and discussion. Echinococcosis of the right lung was found in 29 patients, of the left lung in 17 patients. In 76% of cases, cysts were located in the lower lobe. Combined echinococcosis of both lungs was observed in 7 patients, the largest number of echinococcal cysts were also located in the lower lobe of both lungs. With recurrent echinococcosis of the lungs, solitary cysts were detected only in 24% of cases, mostly patients with multiple and combined echinococcosis prevailed in 76% of cases (Table 1).

Table 1.

Distribution of patients by localization of echinococcal cysts

The nature and localization of cysts		Number of patients	
		Abs.	%
Solitary echinococcosis	Right lung	6	11,3
	Left lung	7	13,2
Multiple echinococcosis	Right lung	23	43,4
	Left lung	10	18,9
Combined echinococcosis		7	13,2
Total		53	100

Depending on the size of the cyst, the patients were distributed as follows: small cysts were detected in 6 patients, medium ones in 24 patients, large cysts in 17 patients and in 6 patients the cysts were gigantic in size over 20 cm. Complicated cysts were seen in 15 patients, i.e. in 28% of cases. Among them, suppuration of the cyst was in 7 patients, a breakthrough of the cyst in the bronchus was noted in 4, and in 3 patients the breakthrough was in the pleural cavity. In the 1st case there was profuse hemoptysis. Studies were carried out during preoperative preparation and in dynamics until the normalization of indicators in the postoperative period [1,4].

Modification of *Echinococcus hominis* (Fig. 1) was noted in 20 (37.7%) patients, *Echinococcus veterinorum* (Fig. 2) was noted in 27 (50.9%) patients, and *Echinococcus acephalocystis* was noted in 6 (11.3%) cases.

The nature of the morphological form was finally judged intraoperatively. The modification of *Echinococcus hominis* differs in that inside the cyst, in addition to the hydatid fluid, brood capsules with protoscolexes, there are child, and sometimes granddaughter bubbles. Maternal cysts macroscopically have a matte, rough surface and are milky white or whitish yellow in color, as shown on the slide. With this form, scolex migration is noted beyond the chitinous membrane into the thickness, or even beyond the fibrous capsule, and exogenous budding occurs with the growth of an echinococcal cyst. It was with this modification that relapses of the disease were observed at the site of preexisting cysts.

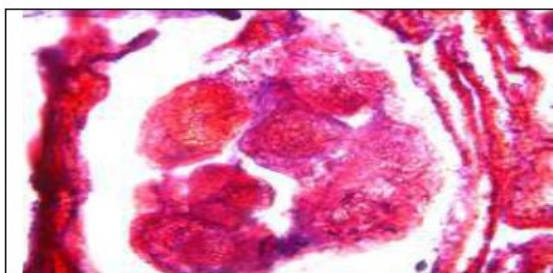


Fig. 1. The structure of an echinococcal cyst of the *Echinococcus hominis* modification. *Echinococcus scolex* in the thickness of the fibrous capsule (staining with hematoxylin-eosin, magnification x 400).

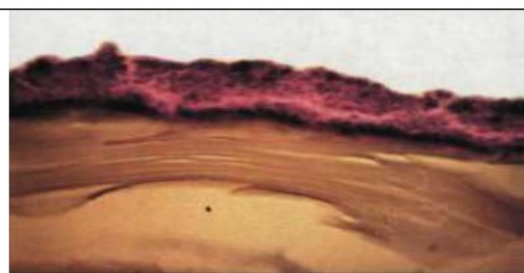


Fig. 2. The structure of an echinococcal cyst of the *Echinococcus veterinorum* modification (staining with hematoxylin-eosin, magnification x200).

In the form of *Echinococcus veterinorum* disease, only brood capsules and echinococcal fluid are present inside the laurel cysts. The formation of child bubbles does not occur. *Echinococcus veterinorum* is perhaps the most aggressive form of the existence of the parasite, which is due to the high pressure of the hydatid fluid, which contains a large number of viable scolexes, which, at the slightest violation of the integrity of the membrane, enter the pleural cavity, causing massive damage to the internal organs by echinococcosis [7]. According to our data, this form prevailed in the largest number of cases (51%).

Laurocysts of the third modification of *Echinococcus acephalocystis* (Fig. 3) were noted in 6 cases. These types of cysts are characterized by the absence of brood capsules and protoscolexes and are more common in animals than in humans.

Preoperative diagnosis of this modification of cysts presents great difficulties. The radiological and echographic characteristics of such cysts are very similar to non-parasitic lung cysts. Histological examination of the germinal membrane showed that its entire surface is subject to dystrophic changes, brood capsules are absent. Therefore, these cysts are unable to produce germline elements.



Fig. 3. The structure of an echinococcal cyst of the modification *Echinococcus acephalocystis*.

(hemotoxylin-eosin stain, magnification x 200).

Conclusions. Thus, 3 morphological modifications of lung echinococcosis were identified: *Echinococcus veterinorum*, *Echinococcus hominis* and *Echinococcus acephalocystis*, each of which has its own specific structure, which differs primarily in the structure of the germinal layer of the parasite. An analysis of the morphological characteristics of echinococcal cysts of the lungs showed that recurrent echinococcosis most often occurred with *Echinococcus veterinorum* (50.9%), *Echinococcus hominis* (37.7%), and with *Echinococcus acephalocystis* relapses of the disease were not observed, and if they did occur (6-11.3%), then this is due to reinvasion of the parasite. The results of treatment of echinococcal cysts of the lungs largely depend on a differentiated approach, taking into account the morphological form of an echinococcal cyst and adherence to the principles of aparasitism and antiparasitism.

BIBLIOGRAPHY:

1. Каримов Ш.И. Проблемы и перспективы хирургического лечения больных эхинококкозом печени и легких / Ш.И.Каримов, Н.Ф.Кротов, В.Л.Ким, У.Б.Беркинов // *Анналы хирургической гепатологии*. 2008. - Т. 13, № 1. - С. 56 - 60.
2. Салимов Ш.Т. и др. Эффективность традиционных и торакоскопических эхинококкэктомий легкого у детей // *Детская хирургия*. – 2012. – №. 4. – С.24-29.
3. Черноусов А.Ф., Мусаев Г.Х., Абаршалина М.В. Современные методы хирургического лечения сочетанного эхинококкоза легких и печени // *Хирургия. Журнал им. Н.И. Пирогова*. – 2012. – №. 7. – С. 12-17.
4. Шамсиев Ж.А. Лечение эхинококкоза печени и легкого у детей (клинико-экспериментальное исследование): /автореф дис. ... кандидата медицинских наук. – Уфа, 2008. – 25 с.
5. Шангареева Р.Х., Ишимов Ш.С. Рецидив эхинококкоза легкого у детей // *Хирургия. Журнал им. Н.И. Пирогова*. – 2012. – №. 3. – С. 18-24.

6. Шевченко Ю. Л., Назыров Ф. Г. Хирургия эхинококкоза. М.: Династия, 2016. - С. 288.
7. Эргашев Н.Ш., Пирназаров Б.Т. Клиника, диагностика и результаты хирургического лечения детей с осложненным эхинококкозом легких //Врач-аспирант. – 2011. – Т. 46. – №. 3.3. – С. 404-408.
8. Islamov Sh.E. Subjectivity in defects in rendering medical aid. //European science review, Vienna, 2018. - №11-12. – P. 95-97.
9. Islamov Sh.E., Kamalova M. Morphological features of ischemic and hemorrhagic brain strokes //Journal of Critical Reviews. 2020. - Vol. 7, iss. 19. - P. 2630-2634.
10. Islamov Sh.E., Kamalova M.I., Khaidarov N.K. Clinical and demographic quality of life for patients with ischemic stroke in Uzbekistan //ACADEMICA an International Multidisciplinary Research Journal. Vol.10, Issue 10, October 2020 – 10.5958/2249-7137.2020.01213.6